

# Master's Surgical Technique: Surgical Treatment of Trigger Thumb and Trigger Finger

*Suzanne E. Steinman MD*

*Seattle Children's Hospital, Department of Orthopaedics and Sports Medicine, Seattle, WA*

**Abstract:** Trigger thumb and trigger finger in children both can result in a painful “triggering” or fixed contracture of the digit. Although they clinically present in a similar fashion, they have quite different treatment methods. Trigger thumb is an acquired condition, with observation for spontaneous resolution as the initial treatment. If trigger thumb fails to resolve with observation, then surgical treatment involves release of the A1 pulley. Conversely, trigger finger is usually due to a congenital difference in the finger flexor anatomy but can be due to metabolic, inflammatory, and other conditions. Initial treatment of trigger finger involves extension splinting, but in cases requiring surgical treatment A1 pulley release and excision of a slip of the flexor digitorum superficialis tendon is typically needed. It is crucial for the treating provider to understand these differences in diagnosis and treatment to ensure the best outcome of these similar but unique conditions.

## **Key Concepts:**

- Trigger thumb is an acquired condition.
- If trigger thumb fails to resolve with observation, then surgical treatment involves an A1 pulley release.
- Trigger finger is usually due to a congenital difference in the finger flexor anatomy but can be due to metabolic, inflammatory, and other conditions. These must be ruled out.
- If trigger finger does not resolve with splinting, then surgical treatment often involves not only A1 pulley release but also an excision of a slip of the flexor digitorum superficialis tendon.

## **Introduction**

Trigger thumb is a very common, acquired condition in children that can result in a painful “triggering” or fixed contracture of the thumb interphalangeal joint due to a mismatch in the size of the flexor pollicis longus tendon near the A1 pulley. This is not from inflammation, so steroid injections and nonsteroidal medications do not have a role in treatment. It usually presents between the ages of 1 to 4 years old. While spontaneous resolution with observation and stretching is possible, this typically takes several years. Other nonoperative treatments such

as stretching and splinting are ineffective and therefore not recommended. Surgical treatment is open A1 pulley release. The differential diagnosis for this condition includes congenital clasped thumb, thumb-in-palm deformity, and trauma.

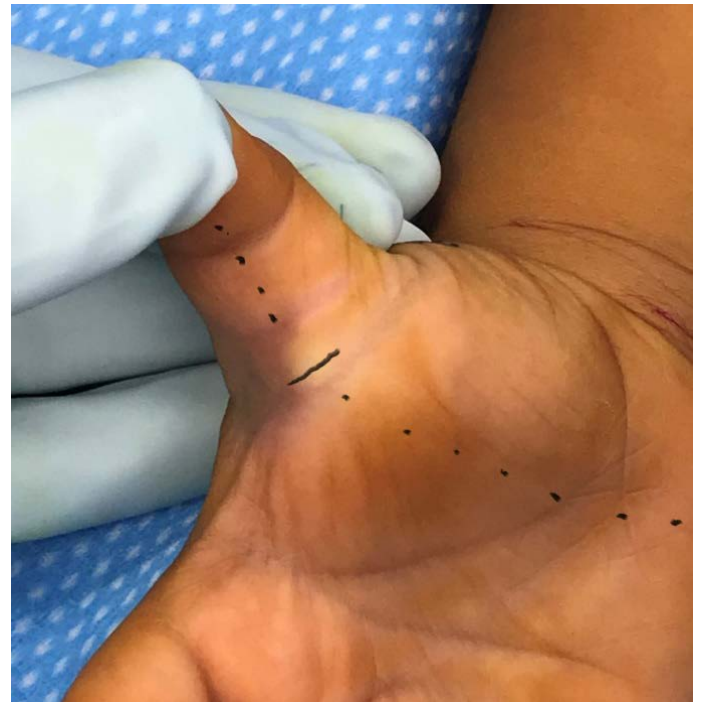In contrast, trigger finger is a “popping or triggering” or fixed flexion of the proximal interphalangeal joint of the fingers other than the thumb. It is most commonly due to an anatomic variant in the flexor tendon mechanism.

This can include decussation of the flexor digitorum superficialis (FDS) proximal to the A1 pulley or an aberrant insertion of the lumbrical muscle. Other anatomic abnormalities of the FDS and flexor digitorum profundus (FDP) tendon that can result in triggering include cysts, nodules, and calcific tendonitis resulting in a size mismatch between the tendons and tendon sheath/pulley system.<sup>1,2</sup> Like trigger thumb, trigger finger usually presents between the ages of 1 to 4 years old, but is 10 times less frequent than trigger thumb.<sup>3</sup> Treatment is different than trigger thumb in that nonoperative treatment can be effective. As such, night splinting is the initial treatment method offered. If surgery is required, it is a much more extensive procedure requiring release of the A1 pulley, sometimes A3, and often excision of a slip of FDS tendon. This condition can be associated with syndromes like mucopolysaccharidosis (MPS), juvenile rheumatoid arthritis, multiple hereditary exostosis, Ehlers-Danlos, Down syndrome, and other nervous system disorders; therefore, these must be considered in the initial assessment.

## Diagnosis

The diagnosis of trigger thumb and trigger finger can usually be made by history and clinical exam. The patient usually presents with “popping” of the thumb or finger with motion or with a fixed contracture of the thumb IP or finger PIP joint. For trigger thumb, there is a palpable nodule usually proximal to the A1 pulley called “Notta’s node” that moves with motion of the flexor tendon. Occasionally, this nodule can get stuck distal to the A1 pulley and block flexion after a period of triggering; thus, careful examination of the tendon and active and passive motion of the thumb is required. Routine imaging of the thumb is not required.

For trigger finger, there often is not a palpable nodule in the tendon, but a “clicking or popping” can be felt near the PIP joint as the patient moves the finger. If multiple digits are involved, it is imperative to ensure that there is no underlying metabolic disorder or syndrome associated with this finding. Imaging is not routinely required in trigger finger either unless there is a need to exclude a

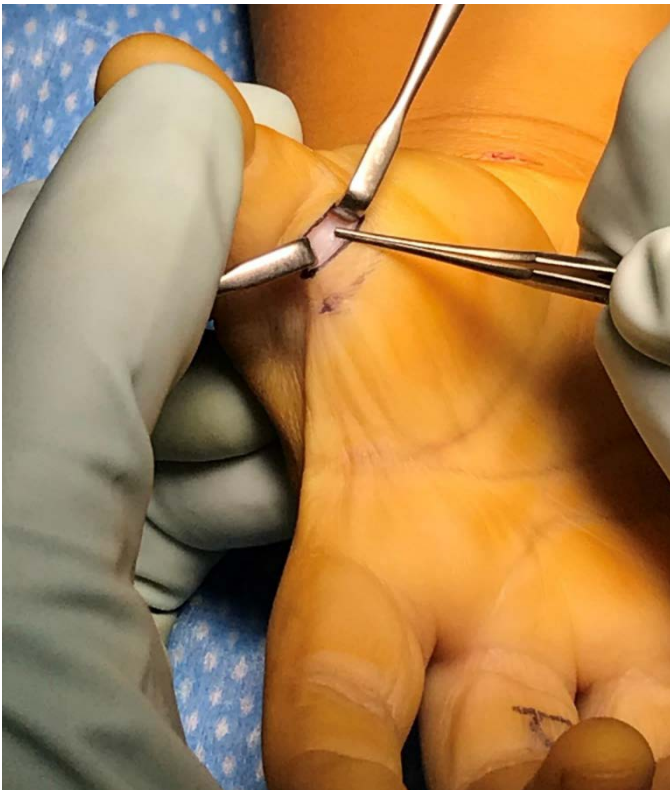

**Figure 1.** Incision for trigger thumb release. Dotted line marks line to hook of hamate to ensure the incision is not too radial.

fracture due to history of trauma or if there is concern for bony lesion such as an osteochondroma.

## Treatment Decision Making

The initial treatment for trigger thumb is observation, as other nonoperative treatments, such as stretching and splinting, are rarely effective. Surgical indications for trigger thumb are painful triggering or prolonged fixed IP flexion contracture with a palpable Notta’s node proximal to the A1 pulley. It is commonly recommended that if it this condition has not resolved after 2 years or by the age of 4, then A1 pulley release should be performed as there is limited chance for spontaneous recovery.<sup>4</sup> Occasionally, patients will develop pain in the thenar region from accommodating the flexed thumb position. This thenar pain is another relative indication for surgery. Trigger thumb release is typically delayed until at least the age of 2 to help decrease any potential risk from anesthesia, allow time for spontaneous resolution of the condition, and assess for development of trigger thumb on the contralateral side, which is seen in up to 25% of cases.<sup>5</sup>



**Figure 2.** Exposure of A1 pulley (at the tip of forceps) with neurovascular bundles retracted

The initial treatment for trigger finger is nighttime extension splinting. Splinting is discontinued once triggering has resolved. If after at least 3 months of nonoperative treatment the patient is still unable to actively extend their finger, requires passive extension to straighten the finger fully, or if the triggering is painful or significantly interrupts function, then surgical intervention is indicated.

### Preoperative Planning

For trigger thumb, it is crucial to examine both thumbs preoperatively to ensure that this condition has not developed on the contralateral side. If the child is older than 4 years or if the thumb has been stuck flexed for a prolonged period, a lateral radiograph can identify any articular changes at the IP joint that could affect the ability to achieve full extension immediately postop. These changes include beaking of the proximal phalangeal head and irregularity of the base of the distal phalanx, often remodel after release and nighttime splinting.

For trigger finger, a thorough history and physical exam are required to ensure there is no suggestion of underlying metabolic, rheumatologic, or other syndromes that may be associated with trigger finger. Laboratory studies or further imaging may be required if the history is concerning, especially if multiple digits are involved.

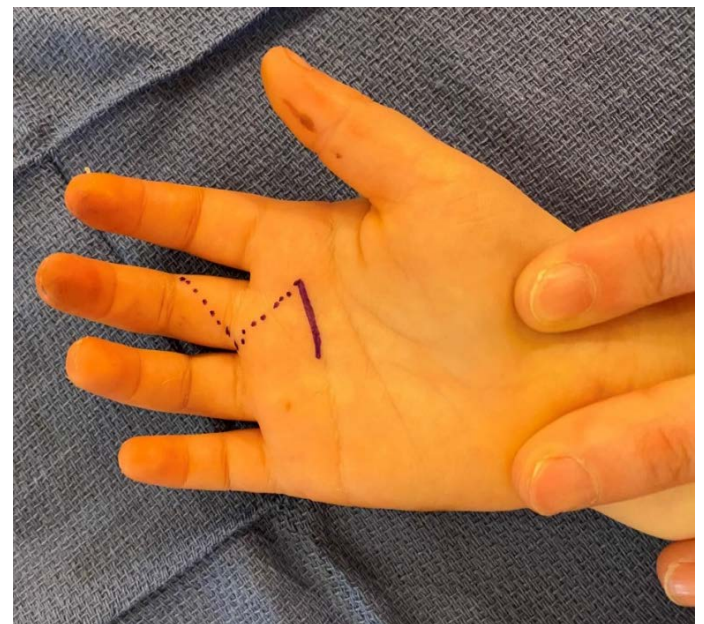
### Operative Techniques

The patient is positioned supine for both trigger thumb and trigger finger release with a hand table attachment. A lead hand can be helpful for trigger digit release.

### Trigger Thumb Release

The procedure is performed under a median nerve block at the carpal tunnel and tourniquet. A horizontal incision is planned just distal to the proximal thumb flexion crease over the palpable nodule (Figure 1), (may be slightly proximal to nodule in cases of thumb stuck in extension).

Ensure that the incision is not too radial, which can place the radial digital nerve at risk by planning surgical incision on a line from the center of the child's thumbprint to the hook of the hamate (Figure 1). The skin incision should be carefully made just through the skin to prevent

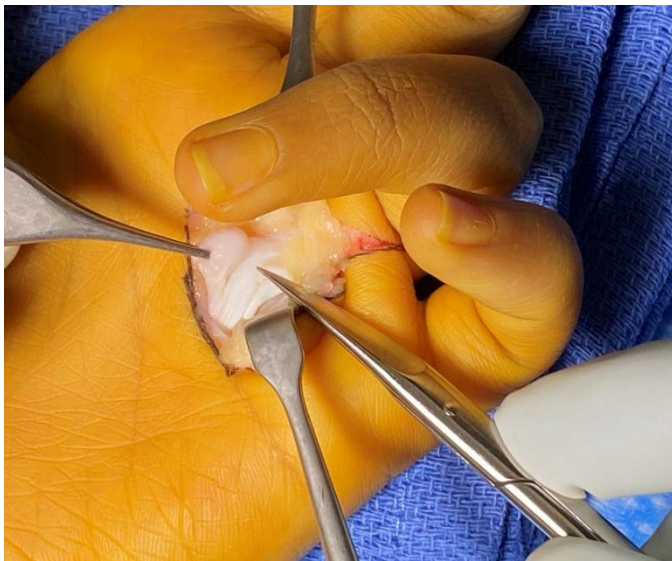


**Figure 3.** Incision for trigger finger release



injury to the superficially located tendon and radial digital nerve. Blunt dissection is used to visualize the A1 pulley, and the radial and ulnar neurovascular bundles are retracted with small Ragnell retractors (Figure 2).

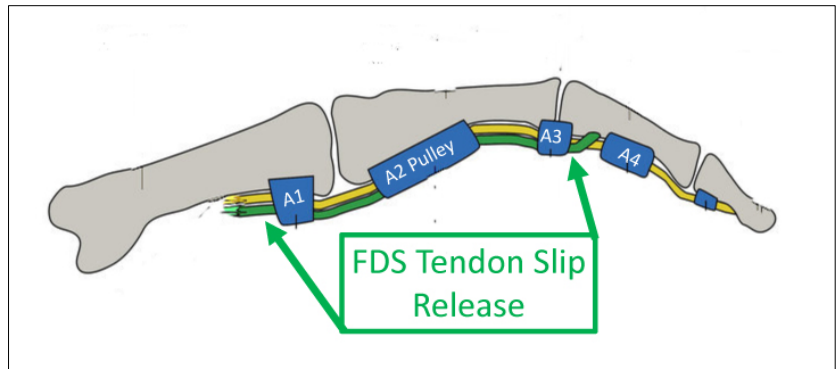
Next, the A1 pulley is incised with a #15 or beaver blade and then released fully proximally and distally using small scissors (Litter's). Check the release by simulating active FPL flexion by maximally extending the wrist and then squeezing the FPL muscle belly in the distal third of the forearm. Full extension of the thumb can be tested with tenodesis effect by maximally flexing the wrist. Once the release is complete, irrigate and close with plain gut (5.0), place sterile dressing, and then short arm thumb spica cast (soft roll preferred for younger children) for 10-14 days. This protects the wound and also gives stretch to thumbs that have developed soft tissue contracture from being held in flexion. Regular and full activities are allowed once the cast is removed.



**Figure 4.** After exploration of the trigger finger, it became apparent a nodule was the causative factor.

### Trigger Finger Release

Trigger finger release can be performed using a regional block for whichever digit is involved and a tourniquet.



**Figure 5.** Locations of FDS Tendon Slip Release if still triggering after A1 pulley Release.

Make an extensile incision starting at A1 pulley and extending distally with Brunner incision (Figure 3).

Dissect bluntly to expose the flexor tendon sheath, taking care to identify and retract the neurovascular bundles to avoid injury. Identify the edge of the A2 pulley and then fully release the A1 pulley. Assess motion as previously discussed for thumb. If still triggering, then explore the FDS and FDP tendons for proximal decussation, fraying, nodules, or aberrant lumbrical muscle (Figure 4).

Sequentially perform excision of a slip of FDS tendon (it does not matter which slip of FDS tendon is excised unless specific pathology is identified in one) followed by release of A3 pulley and partial release of A2 pulley until triggering resolves (Figure 5).

Irrigate and close with plain gut (5.0), place sterile dressing and then splint or cast for 2 weeks to allow wounds to heal. Start active and passive range of motion once out of postoperative dressing and continue nighttime splinting if any residual contracture. The patient may resume regular activities once wounds are healed and motion has returned.

### Complications

Complications are very rare in trigger thumb release. To prevent radial digital nerve injury, take care in incision planning, perform under loupe magnification, and perform open, not percutaneous release. Although rare,

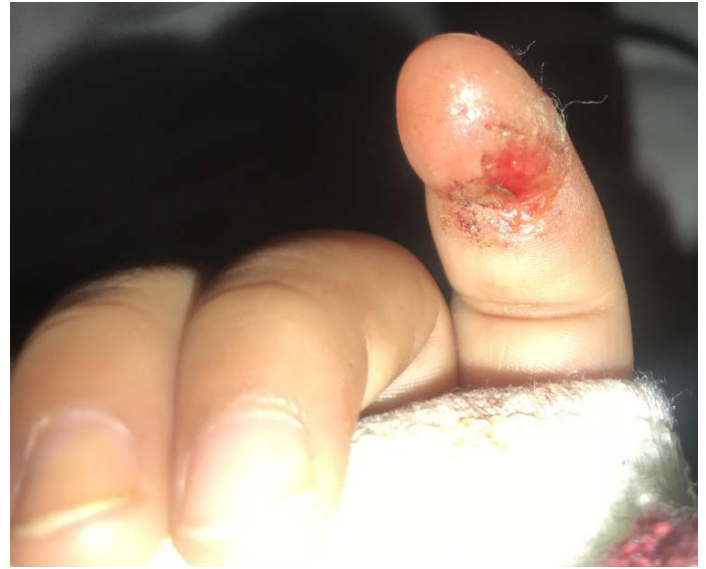recurrence can occur with incomplete release of oblique bands of the pulley so check motion intraoperatively to ensure complete release. Take care not to excessively release the thumb flexor pulley system, as this can result in flexor tendon bowstringing. If recurrence occurs, then treatment is often repeat release. Infection can be prevented by keeping surgical site clean and dry. Cast immobilization helps to keep the surgical site protected and stops the child from picking at the wound while healing. Rare instances of FPL injury have been reported that require repair.

The most common complication in trigger finger release is incomplete release, so careful intraoperative assessment of all potential abnormal anatomic culprits of triggering, sequential release of the involved structures, and intra-operative assessment of finger motion is imperative. Loupe magnification during surgery is helpful to ensure neurovascular bundles are protected and uninjured during surgery.

Lastly, for both procedures, if the child sucks their thumb or regularly chews their fingers, warn parents to protect any fingers that are involved in the block and free from casting, as the child may chew the finger to injury (Figure 6).

## Summary

Trigger thumb is a very common condition found in young children that can be easily treated with surgical release of the A1 pulley if it doesn't resolve with observation. It is important, however, to distinguish trigger thumb from trigger finger, which is much less common and can be associated with metabolic, rheumatologic, or other conditions. It can be treated with splinting, but if surgical release is required, then the treating surgeon must recognize that multiple structures can contribute to



**Figure 6.** Finger injured from chewing while numb from block

the triggering, and all contributing structures must be released at the time of surgery to avoid recurrence.

## References

1. Bae DS, Sodha S, Waters PM. Surgical Treatment of the Pediatric Trigger Finger. *J Hand Surg Am.* 2007;32A(7): 1043-1047.
2. Shah AS, Bae DS. Management of the Pediatric Trigger Thumb and Trigger Finger. *J Am Acad Orthop Surg.* 2012;20: 206-213
3. Cardon LJ, Ezaki M, Carter PR. Trigger finger in children. *J Hand Surg Am.* 1999;24(6):1156-1161.
4. Baek GH, Kim JH, Chung MS, Kang SB, Lee YH, Gong HS. The Natural History of Pediatric Trigger Thumb. *J Bone Joint Surg Am.* 2008;90(5): 980-985.
5. Marek DJ, Fitoussi F, Bohn DC, Van Heest AE. Surgical Release of the Pediatric Trigger Thumb. *J Hand Surg Am.* 2011;36(4):647-65