

Original Research

# Plain Radiographs Have Limited Utility in the Evaluation of Discoid Lateral Meniscus

*Reid P. Schlesinger, BS; Sean M. Rangwani, BA; Neeraj M. Patel, MD, MPH, MBS*

*Ann & Robert H. Lurie Children's Hospital of Chicago, IL*

Correspondence: Neeraj M. Patel, MD, MPH, MBS, Ann & Robert H. Lurie Children's Hospital of Chicago, 225 E. Chicago Ave., Box 69, Chicago, IL 60614. E-mail: neepatel@luriechildrens.org

Received: July 1, 2023; Accepted: September 12, 2023; Published: November 15, 2023

DOI: 10.55275/JPOSNA-2023-756

## Abstract

**Background:** Debate persists regarding the utility of plain film radiography in the diagnosis of discoid lateral meniscus, especially in children. The purpose of this study was to assess various radiographic measurements between healthy children and those with discoid lateral meniscus while controlling for other patient characteristics.

**Methods:** Plain radiographs of 55 pediatric patients with discoid lateral meniscus were matched by age and sex to 55 controls with healthy knees as verified by magnetic resonance imaging. Each radiograph was evaluated for the following parameters: lateral joint space height (both in the central and medial portions of the compartment), medial joint space height, fibular head height, lateral tibial spine height, femoral inter-epicondylar distance, lateral tibial plateau obliquity, and chordal distance of the femoral condyle (medial and lateral).

**Results:** In univariate analysis, children with discoid lateral meniscus had higher median lateral joint space heights ( $p < 0.001$ ) and lower fibular head height ( $p = 0.001$ ) than controls. No other radiographic measurements were significantly different. When adjusting for covariates in regression analysis, the presence of discoid lateral meniscus was predictive of higher lateral joint space heights and lower fibular head height, however, age was also significantly predictive in these models.

**Conclusions:** On plain radiographs, lateral joint space heights and fibular head height are associated with discoid lateral meniscus. However, many previously reported measurements were not predictive. The practical utility of these parameters may be complicated by the impact of age. Advanced imaging is recommended to confirm the diagnosis of discoid lateral meniscus.

**Level of Evidence:** III

### Key Concepts

- Plain films may be used to rule out bony pathology but provide little benefit in ruling in a diagnosis of discoid lateral meniscus.
- Many radiographic findings that were previously associated with discoid lateral meniscus are either inapplicable to skeletally immature X-rays or are confounded by age.

## Introduction

Discoid lateral meniscus (DLM) is the most common meniscal variant with an estimated incidence of 0.4-17%.<sup>1-5</sup> It is most frequently classified according to the Watanabe system, although a newer system based on findings during arthroscopy was recently designed.<sup>6,7</sup> The origin of DLM is believed to be congenital<sup>1,8-11</sup> and it is often diagnosed during childhood or adolescence. Clinical presentation depends on both the meniscal morphology as well as other factors like the presence or absence of a tear. Knee snapping, popping, clicking, locking, swelling, and/or pain may be present if the meniscus is injured or unstable. If DLM is suspected, the initial diagnostic workup involves clinical examination and plain film radiography followed by possible magnetic resonance imaging (MRI).<sup>12-19</sup>

While MRI is a clinically proven tool for diagnosis of DLM,<sup>12-19</sup> the utility of radiography is less clear. Multiple radiographic features have conventionally been considered suggestive of DLM. However, because the meniscus cannot be directly visualized using plain film radiography, these features are limited to proxy skeletal changes. The use of skeletal findings is especially problematic in younger children, as the radiographic appearance of the knee changes significantly throughout childhood until skeletal maturity is reached.<sup>20-22</sup> Previous studies have assessed the use of these radiographic features in the diagnosis of DLM,<sup>20-30</sup> but few have focused specifically on pediatric patients.<sup>20-23</sup> Findings between studies vary considerably. Differences in lateral joint space height (LJSH), fibular head height (FHH), and the condylar cutoff sign (in skeletally mature knees) have been repeatedly demonstrated between patients with

DLM and normal menisci.<sup>20-22,24,26,28,30</sup> Chordal distance of the lateral femoral condyle (CDLF), an alternative to the condylar cutoff sign, was also significantly different in one study of adult patients.<sup>28</sup> Associations between DLM and at least nine additional unique radiographic measurements have also been reported. However, these results have not been consistently repeated.<sup>20-22,28-30</sup>

Plain radiography is an important first step in the workup of most pediatric knee pathology. However, reliable and practical methods are needed if radiography is to be used diagnostically for DLM. The purpose of this study was to compare various radiographic measurements in children with DLM compared to those with normal meniscal morphology while accounting for other patient characteristics.

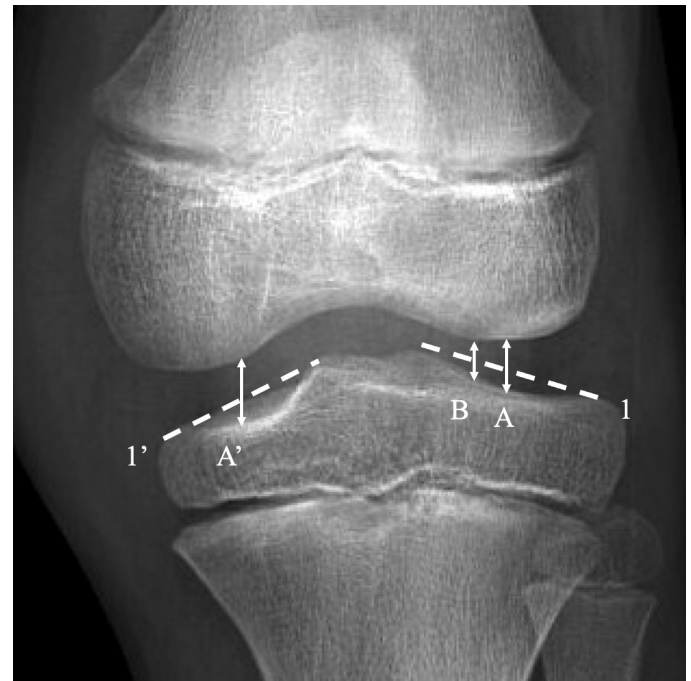
## Materials and Methods

This retrospective case-control study was approved by our Institutional Review Board. Subjects were selected from a database of orthopaedic patients at our institution. Patients under the age of 18 years with an anterior-posterior (AP) radiograph of the knee and MRI confirming DLM within 3 months of the X-ray were included. Since weight-bearing films were not reliably available for many patients, only those with non-weight-bearing X-rays were included. A control group of pediatric patients with both a normal MRI and anterior-posterior radiograph of the same knee before the age of 18 was then generated. Patients with pathologies that could potentially confound the measurements being evaluated in this study (e.g., other knee injuries, deformities, or pathology on MRI) were excluded. Cases

were matched with controls in a 1-to-1 ratio by age and sex without replacement. A 6-month tolerance was applied for matching by age.

The following nine parameters were measured for each radiograph: lateral joint space height – central (LJSH-C), lateral joint space height – medial (LJSH-M), medial joint space height (MJSH), fibular head height (FHH), lateral tibial spine height (LTSH), obliquity of the lateral tibial plateau (OLTP), femoral inter-epicondylar distance (FIED), chordal distance of the lateral femoral condyle (CDLF), and chordal distance of the medial femoral condyle (CDMF). FHH, LTSH, OLTP, and FIED were assessed as described previously by Kim et al.<sup>24</sup> CDLF and CDMF were calculated as described previously by Jiang et al.<sup>28</sup> LJSH-C and MJSH were measured as described previously by Mehta et al.<sup>31</sup> The approach by Mehta et al. was also adapted to generate a new measurement to assess the lateral joint space height closer to the intercondylar notch of the knee that we called LJSH-M. The measurement techniques are depicted in Figures 1-3. These values were also used to generate ratios (LJSH-C/MJSH and LJSH-M/MJSH) comparing the heights of the lateral and medial joint spaces. We sought to evaluate the utility of such ratios in a young population with X-rays of varying skeletal maturity. Each radiograph was measured independently by two reviewers (RPS and SMR) who were blinded to the group assignment and MRI findings.

Statistical analyses were performed with SPSS for Macintosh (v27.0, IMB Corp., Armonk, NY). Calculations included standard descriptive statistics for demographic variables, with means reported  $\pm$  standard deviation (SD) and medians reported with interquartile range (IQR). Inter-observer agreement was assessed via calculation of the intraclass correlation coefficient (ICC), which is reported with 95% confidence intervals (CI). Once good reliability was confirmed between reviewers, the mean measurement values were used for further statistical analysis. The Kolmogorov-Smirnov test was used to assess the normality of continuous variables. Means were compared with independent



**Figure 1.** (A) Lateral joint space height – central (LJSH-C): Distance between the tibial and femoral surfaces at the midpoint of the line depicting the lateral compartment (1) and parallel to the long axis of the tibia; (B) Lateral joint space height – medial (LJSH-M): Distance between the tibial and femoral surfaces at the two-thirds point of the line depicting the lateral compartment (1) and parallel to the long axis of the tibia; (A') Medial joint space height (MJSH): distance between the tibial and femoral surfaces at the midpoint of the line depicting the medial compartment (1') and parallel to the long axis of the tibia.

samples t-tests, and the Mann-Whitney U test was used for nonparametric variables. Analysis of categorical variables was performed using Fisher's exact and Chi-square tests, as appropriate. Univariate analysis was followed by purposeful entry linear or logistic regression, as appropriate, to adjust for confounders.

## Results

A total of 55 knees with DLM were matched with 55 control knees meeting inclusion criteria. A demographic comparison between the two groups is shown in Table 1. Inter-observer agreement was excellent for nearly every measurement (Table 2).

In univariate analysis, patients with DLM had significantly higher median LJSH-C and LJSH-M and



**Table 1. Comparison of Patients With and Without Discoid Lateral Meniscus\***

	Discoid Meniscus	Control	p
Age (y)	10.7±3.5	11.0±3.5	0.7
Body mass index	23.9±8.0	21.1±6.2	0.08
Sex			1.0
Male	28 (50.9)	28 (50.9)	
Female	27 (49.1)	27 (49.1)	
Race			0.03
White	13 (23.6)	29 (52.7)	
Black	3 (5.5)	6 (10.9)	
Asian	2 (3.6)	2 (3.6)	
Multiple	2 (3.6)	0 (0.0)	
Other	30 (54.5)	15 (27.7)	
Unknown	5 (9.1)	3 (5.5)	
Ethnicity			<0.001
Hispanic	36 (65.5)	14 (25.5)	
Non-Hispanic	17 (30.9)	35 (63.6)	
Unknown	2 (3.6)	6 (10.9)	

\*Values reported as mean ± standard deviation or n (%).

radiographic appearance of the skeletally immature knee changes during development. High LJSH or low FHH may suggest the presence of a discoid meniscus, but the absence of these measurements does not definitively rule out DLM. For example, while LJSH-C of 7 mm or more was significantly predictive of DLM, 41.8% of patients with DLM had LJSH-C of <7 mm. Other measurements that have previously been suggested to be predictive of DLM, such as MJSH, LTSH, OLTP, and CDLF, were not found to differ significantly.

The role of radiography in the assessment of DLM has largely been to rule out or identify bony pathology before proceeding to MRI, which allows for direct visualization of structural abnormalities of the meniscus. For example, plain films may identify osteochondritis dissecans of the lateral femoral condyle, which has been associated with

**Table 2. Inter-Observer Reliability\***

	ICC	95% CI	p
LJSH-center	0.97	0.96–0.98	<0.001
LJSH-medial	0.95	0.93–0.97	<0.001
MJSH	0.64	0.47–0.78	<0.001
FHH	0.91	0.87–0.94	<0.001
LTSH	0.83	0.75–0.89	<0.001
FIED	0.99	0.98–0.99	<0.001
OLTP	0.87	0.79–0.92	<0.001
CDLF	0.88	0.78–0.93	<0.001
CDMF	0.91	0.83–0.95	<0.001

\*ICC = Intraclass correlation coefficient; CI = confidence interval; LJSH = lateral joint space height; MJSH = medial joint space height; FHH = fibular head height; LTSH = lateral tibial spine height; FIED = femoral inter-epicondylar distance; OLTP = obliquity of the lateral tibial plateau; CDLF = chordal distance of the lateral femoral condyle; CDMF = chordal distance of the medial femoral condyle.

DLM.<sup>32-34</sup> Prior studies have suggested that X-rays may be used to screen for DLM, with some authors proposing that radiography could partly replace the need for MRI in certain cases.<sup>22,28</sup> Kim et al were the first to demonstrate significant radiographic differences in LJSH and FHH between DLM and normal menisci.<sup>24</sup> These findings were consistently upheld in both adult<sup>28,30</sup> and pediatric patients.<sup>20-22</sup> No other parameters studied by Kim et al were found to be significant. The condylar cutoff sign was not evaluated until a study by Ha et al.<sup>25</sup> With this method, tunnel view radiographs of the knee were used to measure the prominence ratio between the lateral and medial femoral condyles. In adult patients, the authors found a significantly decreased prominence ratio in patients with DLM, suggesting hypoplasia of the lateral femoral condyle serves as a reliable marker of DLM. Subsequent studies confirmed this result in patients with skeletally mature knees but suggested that this method could not be used to reliably detect DLM in patients with open physes.<sup>22,23</sup> To avoid additional imaging

**Table 3. Radiographic Comparison of Patients With and Without Discoid Lateral Meniscus\***

	Discoid Meniscus	Control	p
LJSH-center (mm)**	7.2 (IQR 2.2)	5.5 (IQR 2.1)	<0.001
LJSH-center ≥7 mm	32 (58.2%)	14 (25.5%)	<0.001
LJSH-medial (mm)**	7.0 (IQR 2.8)	5.7 (IQR 2.2)	<0.001
LJSH-medial ≥6 mm	53 (96.4%)	41 (74.5%)	0.001
MJSH (mm)**	8.3 (IQR 2.3)	7.2 (IQR 3.1)	0.01
LJSH-center/MJSH	1.2±0.8	1.0±0.8	0.4
LJSH-medial/MJSH	1.1±0.8	1.0±0.7	0.3
FHH (mm)	12.7±4.2	15.3±5.9	0.01
FHH <16 mm	41 (75.9%)	31 (56.4%)	0.03
LTSH (mm)	9.0±1.9	8.8±1.9	0.5
FIED (mm)	76.3±14.7	75.7±14.2	0.8
OLTP (degrees)	27.7±6.3	28.3±5.7	0.6
CDLF (mm)	2.5±1.4	2.7±1.0	0.4
CDMF (mm)	3.2±1.3	3.3±1.3	0.6

\*Values reported as mean ± standard deviation or n (%), except for variables denoted by \*\*, which are reported as median (interquartile range). IQR = interquartile range; LJSH = lateral joint space height; MJSH = medial joint space height; FHH = fibular head height; LTSH = lateral tibial spine height; FIED = femoral inter-epicondylar distance; OLTP = obliquity of the lateral tibial plateau; CDLF = chordal distance of the lateral femoral condyle; CDMF = chordal distance of the medial femoral condyle.

**Table 4. Predictors of Various Continuous Measurements in Multivariate Analyses**

Variable	Odds Ratio	95% Confidence Interval	p
<b>Lateral joint space height – center</b>			
Discoid meniscus (vs. control)	1.5	1.1–2.1	<0.001
Age	–0.2	–0.2 to –0.08	0.001
<b>Lateral joint space height – medial</b>			
Discoid meniscus (vs. control)	1.4	1.1–2.0	<0.001
Age	–0.09	–0.2 to –0.004	0.04
<b>Fibular head height</b>			
Discoid meniscus (vs. control)	–2.4	–4.1 to –1.6	0.01
Age	0.6	0.3–0.8	<0.001
Sex	0.9	0.8–2.8	0.3

**Table 5. Predictors of Various Categorical Measurements in Multivariate Analyses**

Variable	Odds Ratio	95% Confidence Interval	p
<b>Lateral joint space height - center <math>\geq 7</math> mm</b>			
Discoid meniscus (vs. control)	4.4	1.9–10.5	0.001
Age	0.8	0.7–0.9	0.003
<b>Lateral joint space height - medial <math>\geq 6</math> mm</b>			
Discoid meniscus (vs. control)	9.1	1.9–42.5	0.005
Age	0.9	0.7–1.0	0.1
<b>Fibular head height <math>&lt; 16</math> mm</b>			
Discoid meniscus (vs. control)	2.7	1.1–6.6	0.03
Age	0.8	0.7–0.9	0.001
Sex	2.2	0.9–5.4	0.09

required to capture tunnel views, Jiang et al. applied a similar concept to AP radiographs by measuring chordal distances of the femoral condyles in adult patients.<sup>28</sup> While the ratio between CDLF and CDMF was not significant, CDLF did differ significantly between DLM and normal menisci. However, in contrast to the findings of Ha et al., CDLF was larger in patients with DLM.<sup>25</sup> To our knowledge, the present study is the first to evaluate CDLF and CDMF exclusively in pediatric patients. Our findings indicate that CDLF does not differ significantly between DLM and normal menisci in pediatric patients. This is in keeping with prior studies suggesting that morphology of the lateral femoral condyle is not a reliable predictor of DLM in patients with skeletally immature knees. Other novel measurements including tibial eminence width, lateral slope angle of the medial tibial eminence,<sup>29</sup> and lateral condyle convex angle<sup>30</sup> were also previously shown to be predictive of DLM. However, these have only been demonstrated in single studies of adult patients.

Of the above studies, four have evaluated radiography as a screening tool specifically in pediatric patients,<sup>20-23</sup> which is important, as DLM is a congenital anomaly that often manifests during childhood or adolescence. A major confounding factor in pediatric patients is the changing appearance of the knee on radiography as the skeleton

matures. To overcome this, the most sophisticated model in children to date divided DLM patients into two age groups (5-9 years and 10-16 years).<sup>22</sup> The authors postulated that combining multiple radiographic features into a single predictive model would yield more accurate results than relying on any single measurement alone. The models ultimately yielded 85.9% sensitivity and 60.4% specificity in the 5-to 9-year-old group and 79.6% sensitivity and 90.4% specificity in the 10- to 16-year-old group. Of note, the same measurements were not used for each age group.

Although these models attempt to account for age, there are still notable limitations. Patient age, as used by the authors, is not based on skeletal age and also does not account for sex. Therefore, it is possible, for instance, that the skeletal maturity of a male with a chronological age of 10 years is very different from that of a female with the same chronological age. Furthermore, the practical utility of such a model in a busy clinic setting is unclear, especially if additional advanced imaging is frequently required regardless. For example, if a skeletally immature patient were to have a relatively high LJSH and low FHH with clinical symptoms concerning for DLM, would surgeons feel comfortable indicating surgery without additional imaging? Even if a statistical model were perfectly

predictive of DLM, MRI may still be required for clinical decision-making and surgical preparation. The presence and pattern of tears or instability may affect treatment decisions and require special instrumentation. Plain films can help rule out other pathology, including relatively uncommon conditions that may be missed, like osteochondritis dissecans and tibial spine avulsions. However, the ability of X-rays to confidently “rule in” DLM in young children is doubtful. The authors typically prefer anterior-posterior, lateral, and notch X-rays of the knee in the initial work-up of DLM, as these will generally rule out most bony abnormalities outside of the patellofemoral compartment. Once diagnosis of DLM is confirmed, standing alignment X-rays are obtained since valgus alignment may affect lateral compartment forces.

Limitations of this study include its retrospective design as well as a lack of weight-bearing X-rays. Many of the patients in this study were referred to our institution after obtaining non-weight-bearing X-rays elsewhere. While it is possible that weight-bearing films may affect the data, our clinical practice is typically to avoid additional radiation to children unless it is felt that treatment decisions may be impacted by new X-rays. Furthermore, the addition of weight-bearing X-rays would not affect the influence of age on skeletal appearance, and age was a confounding factor in this study. Another potential limitation is that exact skeletal age was not available. Finally, race was not factored into our multivariate models due to the relatively large amount of missing data. It is unclear whether such factors would affect the results.

In this case-control study of pediatric patients that included a large proportion of skeletally immature children, LJSH and FHH were associated with DLM. However, age was also linked to many of these measurements. Several previously reported measures were not predictive of DLM in this young cohort. Based on these results, plain radiography is best suited to rule out osseous pathology rather than reliably diagnose DLM in a practical manner. Advanced imaging may be

required to confirm the diagnosis and provide clinical recommendations.

## Disclaimer

No funding was received. The authors report no conflicts of interest related to this manuscript.

## References

1. Fleissner P, Eilert RE. Discoid lateral meniscus. *Am J Knee Surg.* 1999;12:125-131.
2. Dickhaut SC, DeLee JC. The discoid lateral-meniscus syndrome. *J Bone Joint Surg Am.* 1982;64:1068-1073.
3. Fritschy D, Gonseth D. Discoid lateral meniscus. *Int Orthop.* 1991;15:145-147.
4. Ikeuchi H. Arthroscopic treatment of the discoid lateral meniscus. Technique and long-term results. *Clin Orthop Relat Res.* 1982;19-28.
5. Middleton DS. Congenital disc-shaped lateral meniscus with snapping knee. *J Br Surg.* 1936;24:246-255.
6. Watanabe MT, Ikeuchi H. *Atlas of Arthroscopy.* New York, NY: Springer-Verlag; 1978.
7. Lee RJ, Nepple JJ, Schmale GA, et al. Reliability of a new arthroscopic discoid lateral meniscus classification system: a multicenter video analysis. *Am J Sports Med.* 2022;50:1245-1253.
8. Aichroth PM, Patel DV, Marx CL. Congenital discoid lateral meniscus in children. A follow-up study and evolution of management. *J Bone Joint Surg Br.* 1991;73:932-936.
9. Clark C, Ogden J. Development of the menisci of the human knee joint. Morphological changes and their potential role in childhood meniscal injury. *J Bone Joint Surg Am.* 1983;65:538-547.
10. Kim S-J, Kim D-W, Min B-H. Discoid lateral meniscus associated with anomalous insertion of the medial meniscus. *Clin Orthop Relat Res.* 1995:234-237.
11. Woods GW, Whelan J. Discoid meniscus. *Clin Sports Med.* 1990;9:695-706.
12. Kim J-G, Han S-W, Lee D-H. Diagnosis and treatment of discoid meniscus. *Knee Surg Relat Res.* 2016;28:255.
13. Kocher MS, Logan CA, Kramer DE. Discoid lateral meniscus in children: diagnosis, management, and outcomes. *J Am Acad Orthop Surg.* 2017;25:736-743.
14. Kramer DE, Micheli LJ. Meniscal tears and discoid meniscus in children: diagnosis and treatment. *J Am Acad Orthop Surg.* 2009;17:698-707.
15. Kushare I, Klingele K, Samora W. Discoid meniscus: diagnosis and management. *Orthop Clin North Am.* 2015;46:533-540.
16. Connolly B, Babyn P, Wright J, et al. Discoid meniscus in children: magnetic resonance imaging characteristics. *Can Assoc Radiol J.* 1996;47:347-354.
17. Stark JE, Siegel MJ, Weinberger E, et al. Discoid menisci in children: MR features. *J Comput Assist Tomogr.* 1995;19:608-611.
18. Samoto N, Kozuma M, Tokuhisa T, et al. Diagnosis of discoid lateral meniscus of the knee on MR imaging. *Magn Reson Imaging.* 2002;20:59-64.
19. Araki Y, Yamamoto H, Nakamura H, et al. MR diagnosis of discoid lateral menisci of the knee. *Eur J Radiol.* 1994;18:92-95.
20. Choi SH, Ahn JH, Kim KI, et al. Do the radiographic findings of symptomatic discoid lateral meniscus in children differ from normal control subjects? *Knee Surg Sports Traumatol Arthrosc.* 2015;23:1128-1134.
21. Milewski MD, Krochak R, Duarte AJ, et al. Do age and weightbearing radiographs affect lateral joint space and fibular height measurements in patients with discoid lateral meniscus? *Orthop J Sports Med.* 2018;6:2325967118760534.



22. Park YB, Ha CW, Jang JW, et al. Prediction models to improve the diagnostic value of plain radiographs in children with complete discoid lateral meniscus. *Arthroscopy*. 2018;34:479-489.e473.
23. Ha C-W, Jang JW, Kim M, et al. The utility of the radiographic condylar cut-off sign in children and adolescents with complete discoid lateral meniscus. *Knee Surg Sports Traumatol Arthrosc*. 2017;25:3862-3868.
24. Kim SJ, Moon SH, Shin SJ. Radiographic knee dimensions in discoid lateral meniscus: comparison with normal control. *Arthroscopy*. 2000;16:511-516.
25. Ha CW, Lee YS, Park JC. The condylar cutoff sign: quantifying lateral femoral condylar hypoplasia in a complete discoid meniscus. *Clin Orthop Relat Res*. 2009;467:1365-1369.
26. Song JG, Han JH, Kwon JH, et al. Radiographic evaluation of complete and incomplete discoid lateral meniscus. *Knee*. 2015;22:163-168.
27. Picard J, Constantin L. Radiological aspects of the discoid meniscus. *J Radiol Electrol Med Nucl*. 1964;45:839-841.
28. Jiang W, Li X, Su H, et al. A new method to diagnose discoid lateral menisci on radiographs. *Knee Surg Sports Traumatol Arthrosc*. 2016;24:1519-1524.
29. Hino T, Furumatsu T, Fujii M, et al. Tibial eminence width can predict the presence of complete discoid lateral meniscus: a preliminary study. *J Orthop Sci*. 2017;22:1084-1088.
30. Lu X, Qian J, Yang B, et al. A new radiographic finding of adult symptomatic discoid lateral meniscus. *Medicine*. 2020;99:e19646.
31. Mehta N, Duryea J, Badger GJ, et al. Comparison of 2 radiographic techniques for measurement of tibiofemoral joint space width. *Orthop J Sports Med*. 2017;5:2325967117728675.
32. Hashimoto Y, Nishino K, Reid JB 3rd, et al. Factors related to postoperative osteochondritis dissecans of the lateral femoral condyle after meniscal surgery in Juvenile patients with a discoid lateral meniscus. *J Pediatr Orthop*. 2020;40:e853-e859.
33. Takigami J, Hashimoto Y, Tomihara T, et al. Predictive factors for osteochondritis dissecans of the lateral femoral condyle concurrent with a discoid lateral meniscus. *Knee Surg Sports Traumatol Arthrosc*. 2018;26:799-805.
34. Deie M, Ochi M, Sumen Y, et al. Relationship between osteochondritis dissecans of the lateral femoral condyle and lateral menisci types. *J Pediatr Orthop*. 2006;26:79-82.